

Advances in Imaging of Lymph Flow Disorders¹

*Charles L. Witte, MD • Marlys H. Witte, MD • Evan C. Unger, MD
Walter H. Williams, PhD, MD • Michael J. Bernas, MS • George C.
McNeill, RT • Anthony M. Stazzone, MD*

Conventional oil-contrast lymphography has long been the mainstay for lymphatic imaging. However, the emergence of computed tomography (CT) and magnetic resonance (MR) imaging has severely curtailed its use. Because of recent improvements and refinements, lymphangioscintigraphy now permits high-resolution imaging of peripheral lymphatic vessels and provides insight into lymph flow dynamics. It is indispensable for patients with known or suspected lymphatic circulatory disorders in confirming the diagnosis and delineating the pathogenesis and evolution of lymphedema. In addition, lymphangioscintigraphy helps evaluate lymphatic truncal anatomy and radiotracer transport. It can also be used to evaluate the efficacy of various treatment options designed to facilitate lymph flow or reduce lymph formation. The procedure is essentially noninvasive, can easily be repeated, and does not adversely affect the lymphatic vascular endothelium. MR imaging complements lymphangioscintigraphy in the monitoring and treatment of more complex lymphatic circulatory disorders, whereas CT facilitates catheter-guided percutaneous sclerosis or obliteration of specific lymphangiectasia or lymphangioma syndromes. Ultrasonography has proved useful in the setting of filariasis. Patients with a provisional diagnosis of peripheral lymphatic dysfunction or idiopathic edema should undergo diagnostic lymphangioscintigraphy and, in some cases, MR imaging to verify diagnostic accuracy, pinpoint the specific abnormality, and help guide subsequent therapy.

Abbreviations: AIDS = acquired immunodeficiency syndrome, TIS = Transport Index Score

Index terms: Lymphatic system, abnormalities, 99.15 • Lymphatic system, CT, 99.1291 • Lymphatic system, diseases, 99.851, 99.852 • Lymphatic system, flow dynamics, 99.92 • Lymphatic system, MR, 99.12941 • Lymphatic system, radionuclide studies, 99.12974 • Lymphatic system, US, 99.1298

RadioGraphics 2000; 20:1697-1719

¹From the Departments of Surgery (C.L.W., M.H.W., M.J.B., A.M.S.) and Radiology (E.C.U., W.H.W., G.C.M.), University of Arizona College of Medicine, 1501 N Campbell Ave, Rm 4406, PO Box 245063, Tucson, AZ 85724-5063. Received May 19, 1999; revision requested May 25 and received July 21; accepted July 23. Supported in part by a grant from Beiersdorf-Jobst, Inc. **Address correspondence to** C.L.W. (e-mail: lymph@u.arizona.edu).

Introduction

It is axiomatic that in patients with suspected arterial or venous disease, the diagnosis should be verified before definitive treatment is undertaken. In peripheral arterial dysfunction, corroboration takes the form of absent palpable pulses, decreased ankle or brachial arterial pressure indexes, deranged anatomy at arteriography, or calcification of distal arteries at radiography. In venous disorders, corroboration takes the form of prominent venous varicosities or findings of valve incompetence or luminal occlusion at impedance plethysmography, duplex Doppler ultrasonography (US), and contrast material-enhanced or radionuclide phlebography.

Unlike the standard evaluation of disorders of the blood vasculature, the diagnosis of lymphatic circulatory disorders usually rests primarily on clinical impression (ie, suggestive history and characteristic findings at physical examination). Thus, patients who have undergone dissection or irradiation of the axilla for staging or treatment of breast cancer and later develop unilateral arm edema are assumed to have secondary lymphedema. Similarly, in certain highly endemic regions of the world, peripheral edema is occasionally linked to adult filarial worms lodged in the limb lymphatic system, either owing to the presence of microfilariae in the bloodstream or, more commonly, simply on the basis of statistical probability. Yet, even in these relatively "straightforward" situations, it remains clinically desirable, as with blood vasculature disorders, to pinpoint the anatomic and physiologic derangement, particularly before embarking on a treatment regimen that is likely to require a lifelong commitment and that may prove ineffective or even harmful if the diagnosis of lymphedema is incomplete or incorrect.

In this article, we review the background of lymphatic imaging and discuss lymphangioscintigraphic technique. We also discuss and illustrate the advantages and limitations of lymphangioscintigraphy as well as MR imaging and CT in the evaluation of lymph flow disorders, including primary and secondary lymphatic dysplasia and primary and secondary lymphedema.

Background of Lymphatic Imaging

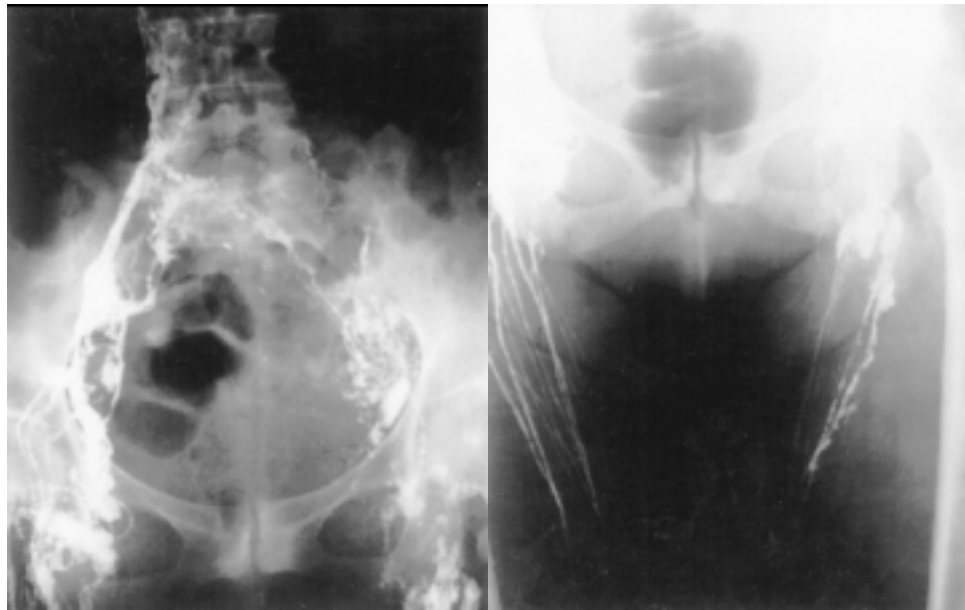
In the past, corroboration of the nature and extent of lymphatic dysfunction required the cumbersome, inconvenient, and usually one-time procedure of conventional or direct lymphography (1). Typically, this technique involved depiction of dermal lymphatic vessels with intradermal injection of a vital blue or green dye into the hand or foot. After a small "cut-down," the exposed lymphatic vessel containing dye was cannulated and an oily medium slowly injected over many hours under graded pressure to depict both lymphatic collectors and regional draining lymph nodes. Conventional lymphography has been the standard of reference for definitive delineation of the lymphatic system. However, the emergence and ease of use of computed tomography (CT) and magnetic resonance (MR) imaging for examining lymph nodes (ie, for size rather than architecture), the drawbacks of conventional lymphography (including surgical exposure, damage to the lymphatic endothelium [oil-injury lymphangiopathy], tediousness of dissection, pulmonary oil embolism, and wound infection) (2), and the prevailing pessimism about the effectiveness of treatment of lymphedema have led most physicians to abandon lymphatic imaging and to rely instead on patient history and physical appearance for diagnosis and initiation of therapy.

Despite this background of frustration in lymphedema diagnosis and treatment, the availability of newer imaging techniques, the confusing array of patients with idiopathic swelling, and the increasing number of treatment options now dictate that the prevailing attitudes and approach be revisited. Cases involving peripherally distributed morbid obesity (often termed “lipedema”), edemas of unclear or mixed cause, reflux syndromes associated with genital swelling, or chylous fistulas are either misdiagnosed on strictly clinical grounds or treated haphazardly or with additional risk because the initial impression is either erroneous or poorly defined. Perhaps even more disconcerting is that treatment trials are easily confounded by appropriate treatment for the “wrong” patient or inappropriate treatment for the “right” patient. The recent development and improvement of isotope lymphography (also known as lymphangioscintigraphy) (3), especially the whole-body modification that involves use of a technetium-labeled macromolecule (eg, technetium-99m albumin) as the radiotracer (4), has dramatically changed the playing field. Indeed, as a diagnostic tool for defining anatomic and functional derangement in the lymphatic system or as a method for monitoring treatment protocols (eg, surgical procedures designed to augment lymph return such as lymphatic- or lymph nodal-venous shunt placement), whole-body lymphangioscintigraphy is now the first-line imaging modality for visualization of the lymphatic vasculature (4).

Lymphangio- scintigraphic Technique

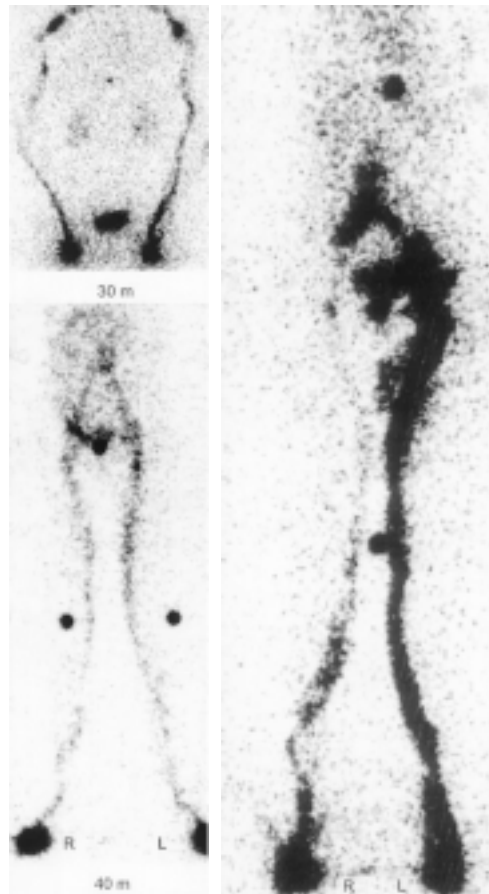
Although considerable variation exists, we have found the following protocol optimal for obtaining clear, comprehensive, and consistent lymphangioscintigraphic images. Because details have been published elsewhere (4), only the key fea-

tures are outlined here. Briefly, 500 μ Ci (18.5 MBq) diluted in 0.05 mL of Tc-99m albumin (Kit Micro, Paramus, NJ; 92%–98% of albumin tightly bound) is injected intradermally to raise a wheal in the web space of the foot or hand (usually between the hallux or pollux and the adjacent digit). Both arms or legs are examined to monitor injection and camera technique, even if one limb appears clinically normal. After 1 minute and again after 10–30 minutes, a high-resolution scintiscan camera (eg, Toshiba Medical Systems, Tustin, Calif) with a parallel hole collimator is passed over the patient to provide a sharp image of radiotracer transport. The macromolecule albumin (MW 69kDa) preferentially (>98%) enters initial lymphatic vessels and, subsequently, lymphatic collectors and regional lymph nodes, where it is readily depicted on scintigrams (Fig 1). After several hours, the radiotracer has largely cleared from the extremity, with residual radiopharmaceutical remaining at the injection site (but decaying to undetectable levels within 24 hours) or in regional nodes (“hot spots”). A wide variety of lymphatic abnormalities can be displayed, and image quality is comparable to that provided by direct (conventional) lymphography (Fig 2). Unlike the latter technique, the isotope method is simple, safe, and readily repeatable. As a result, lymphangioscintigraphy has largely supplanted conventional oil-contrast lymphography as the standard of reference for diagnostic imaging (3,4) and allows treatment planning based on a “positive” image of lymphatic dysplasia rather than on “negative” reasoning from depiction of an intact venous system at US or phlebography, a normal serum albumin level, or an unremarkable abdominal CT scan or MR image.



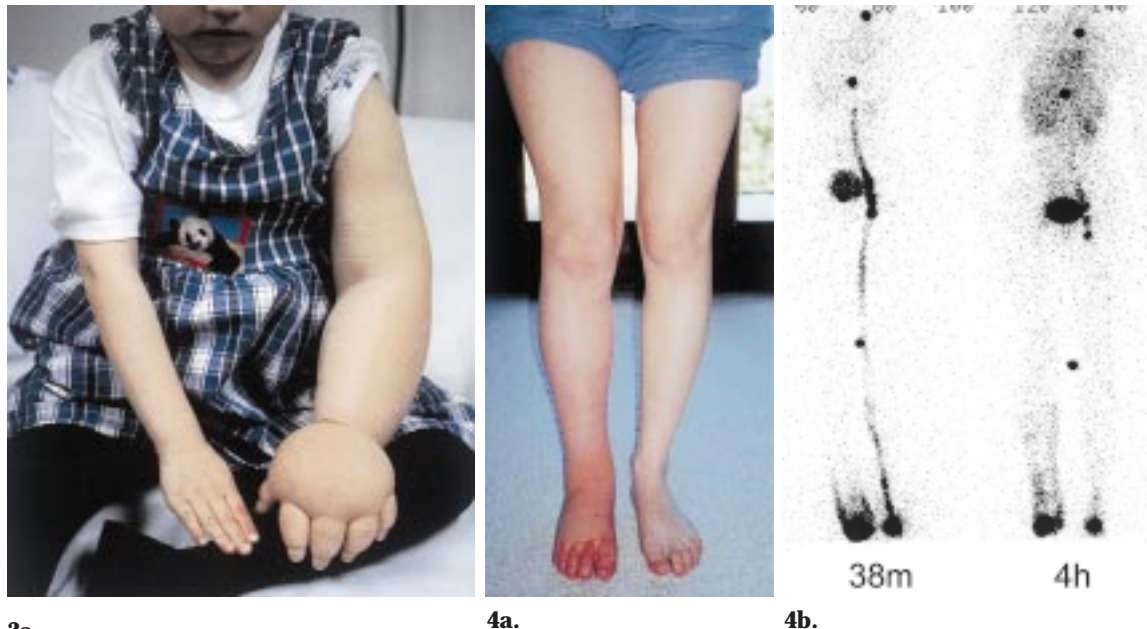
2a.

Figures 1, 2. (1) Normal lymphangioscintigraphic findings. Lymphangioscintigrams of the arms (top) and legs (bottom) obtained 30 and 40 minutes after injection of radiotracer, respectively demonstrate normal findings. On lymphangioscintigrams obtained 4 hours later (not shown), the radiotracer (Tc-99m albumin) had cleared from each extremity. (2) Idiopathic lymphedema of the left leg in a 69-year-old woman. Conventional oil-contrast lymphograms (a) and lymphangioscintigram (b) show dermal backflow in the left thigh with premature left-to-right crossover in the pelvis.



1.

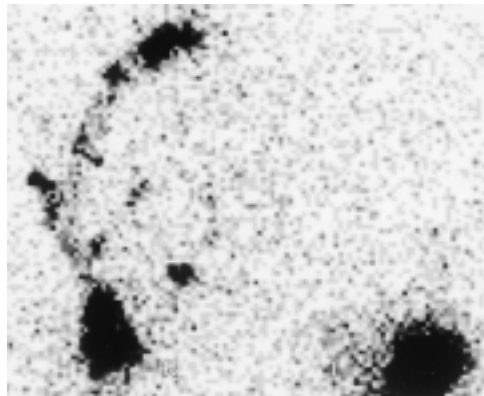
2b.



3a.

4a.

4b.



3b.

Figures 3, 4. (3) Congenital lymphedema of the left arm in a 3-year-old girl. (a) Clinical photograph demonstrates marked enlargement of the patient's left arm compared with the normal right arm. (b) Lymphangioscintigram demonstrates absence of radiotracer transport (aplasia) in the left arm with normal findings in the right arm. MR imaging demonstrated that, except for edema, the blood vessels and soft tissues were unremarkable. (4) Congenital lymphedema in a 16-year-old girl. (a) Clinical photograph shows enlargement of the right leg. (b) Lymphangioscintigrams obtained 38 minutes (left) and 4 hours (right) after injection of radiotracer demonstrate aplasia of right leg lymphatic vessels and normal transport in the left leg.

Lymphangioscintigraphy in the Evaluation of Lymph Flow Disorders

Primary Lymphatic Dysplasia

Although the prototypical disorder involving a primary disturbance of lymph flow is Milroy disease, this hereditary entity is rare. Most patients with primary lymphedema have either unilateral or bilateral swelling (involving the legs more often than the arms), and the occurrence of edema is an isolated phenomenon with no familial pattern. In this regard, primary lymphatic dysplasia resembles other angiodysplastic syndromes such as Klippel-Trenaunay disorder, which is often associated with venous (Klippel-Trenaunay-Servelle syndrome) (5) and lymphatic abnormalities, occasionally coexists with arterial disturbances (Klippel-Trenaunay-Weber syndrome) (6), and seems to arise as a somatic mutation in

utero. In contrast, Milroy disease is an inherited autosomal dominant disorder with high penetrance in which usually one parent and half of the siblings are afflicted—most commonly at birth or soon thereafter—with lymphedema of one or both legs and occasionally of the arms, face, or other body parts (7).

Primary Lymphedema

The clinical manifestations of primary lymphedema occur in patients from birth to over 25 years of age. Thus, it is not surprising that lymphangioscintigraphic findings in affected patients vary considerably. Nonetheless, certain features stand out, most of which are distinct from lymphangioscintigraphic changes in secondary lymphedema. Most prominent is either the complete absence of radiotracer transport (Figs 3, 4) or early migration of radiotracer into the interstitium (dispersion or dermal backflow) without evidence of lymphatic

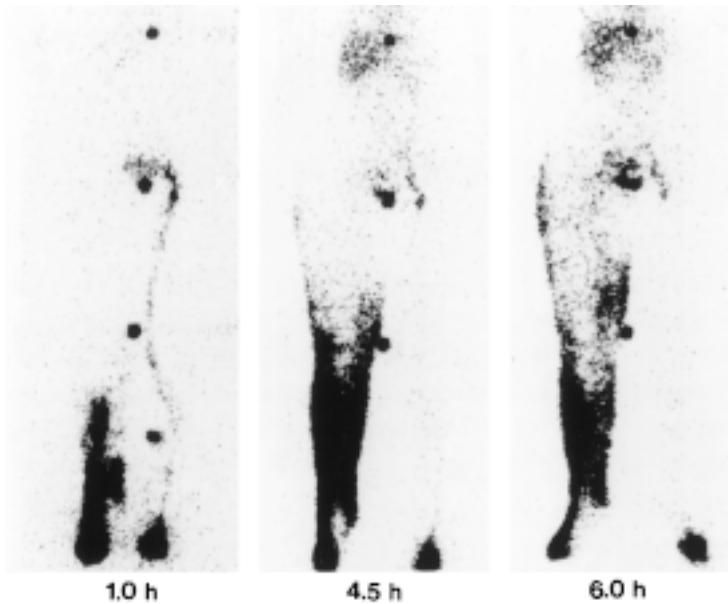


Figure 5. Lymphatic hypoplasia in a 39-year-old woman with a 20-year history of right leg lymphedema (lymphedema precox). Lymphangioscintigrams obtained 1 (left), 4½ (middle), and 6 (right) hours after injection of radiotracer demonstrate a lack of lymphatic collectors in the right leg with progressive filling of superficial skin lymphatic vessels (dermal backflow), findings that are consistent with lymphatic hypoplasia.

truncal flow (ie, truncal aplasia or hypoplasia) (Fig 5). In this context, it is imperative that a distinct wheal be raised at the site of radiotracer injection to verify intradermal instillation. On occasion, we (like others) have observed factitious failure of radiotracer movement despite an intact lymphatic system when the radiopharmaceutical has been introduced into the subcutaneous tissue (8).

In contrast to patients with primary lymphatic disorders in whom peripheral edema is apparent soon after birth or within the first 5 years of life, another cohort of patients develop lymphedema at puberty or thereafter up to 25 years of age. In such cases, disease is classified as lymphedema precox, although it is not entirely clear whether affected patients represent a homogeneous subset. Rarely, the condition is familial and associated with distichiasis (double row of eyelashes). Whereas most patients with lymphedema precox have imaging findings consistent with primary lymphedema (ie, lack of lymph collectors, dermal diffusion, delayed transport [Figs 4, 5]), other patients paradoxically have intact collectors, rapid regional transport, and delayed dermal diffu-

sion. In conjunction with findings at direct (oil-contrast) lymphography (hyperplastic lymph trunks or obliterated [fibrotic] lymph nodes [Fig 6]), these findings favor an acquired (versus congenital) origin. The Transport Index Score (TIS) (9) is also instructive in this setting. The TIS allows semiquantification of peripheral lymphatic radiotracer transport by means of a relative value score (0–9) for each marker. The scores are added together to arrive at an overall numeric index derived from objective and subjective criteria based on lymphatic and nodal temporal and spatial distribution of the radionuclide and its rate of appearance in regional lymph nodes (groin or axilla). The TIS ranges from 0 (normal) to 45 (pathologic) and is calculated as

$$TIS = K + D + 0.04T + N + V,$$

where K = lymphatic transport kinetics (degree of transport delay); D = radionuclide distribution pattern (degree of dermal backflow), T = timing of radionuclide appearance in regional lymph nodes (in minutes normalized for 200 minutes, the maximum delay accepted for lymph node appearance), N = demonstration and intensity of lymph nodes, and V = demonstration and intensity of lymphatic collectors (Fig 7).

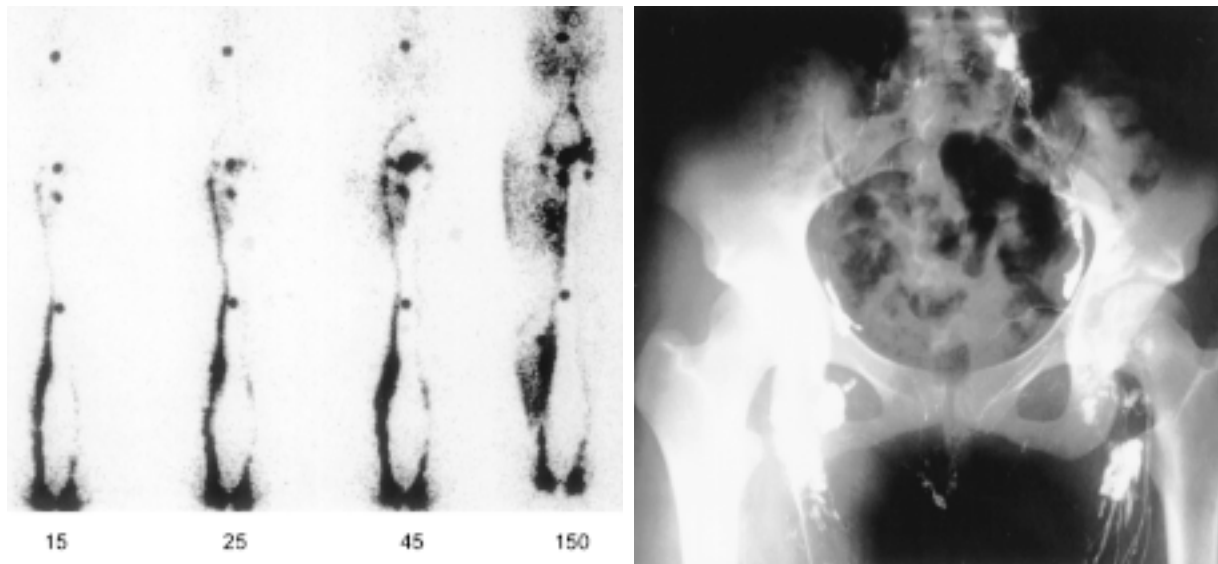


Figure 6. Lymphedema precox in a 16-year-old girl. **(a)** Lymphangioscintigrams obtained 15, 25, 45, and 150 minutes after intradermal instillation of radiotracer show rapid transport to the groin but with prominent dermal backflow in the right leg after 45 minutes. This finding is not typically seen in patients with lymphedema precox (cf Figs 4, 5). **(b)** Conventional lymphogram shows a paucity or obliteration of right-sided parailiac lymph nodes.

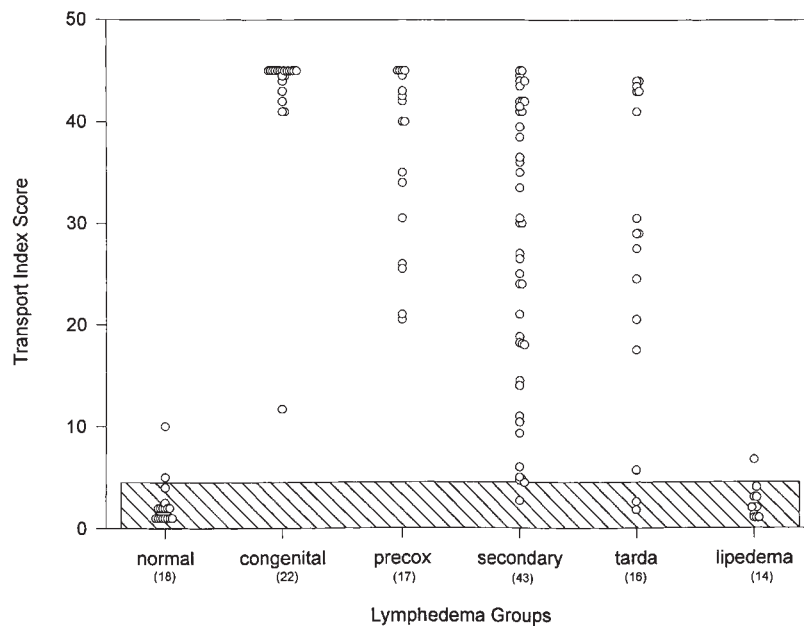


Figure 7. Graph illustrates the lymphatic TIS in 130 patients with various types of lower-limb lymphedema (number of patients with each type in parentheses). Patients with severe (congenital) lymphatic dysplasia almost uniformly had a high TIS, a finding that is indicative of sluggish lymph transport. Note, however, that lymphedema precox and tarda, like secondary lymphedema, exhibit variable changes in lymph transport, a finding that is suggestive of a spectrum of physiologic manifestations and, hence, of different causes. Morbid obesity (“lipedema”) typically displays normal lymph transport. A similar TIS pattern has also been documented for arm lymphedema.

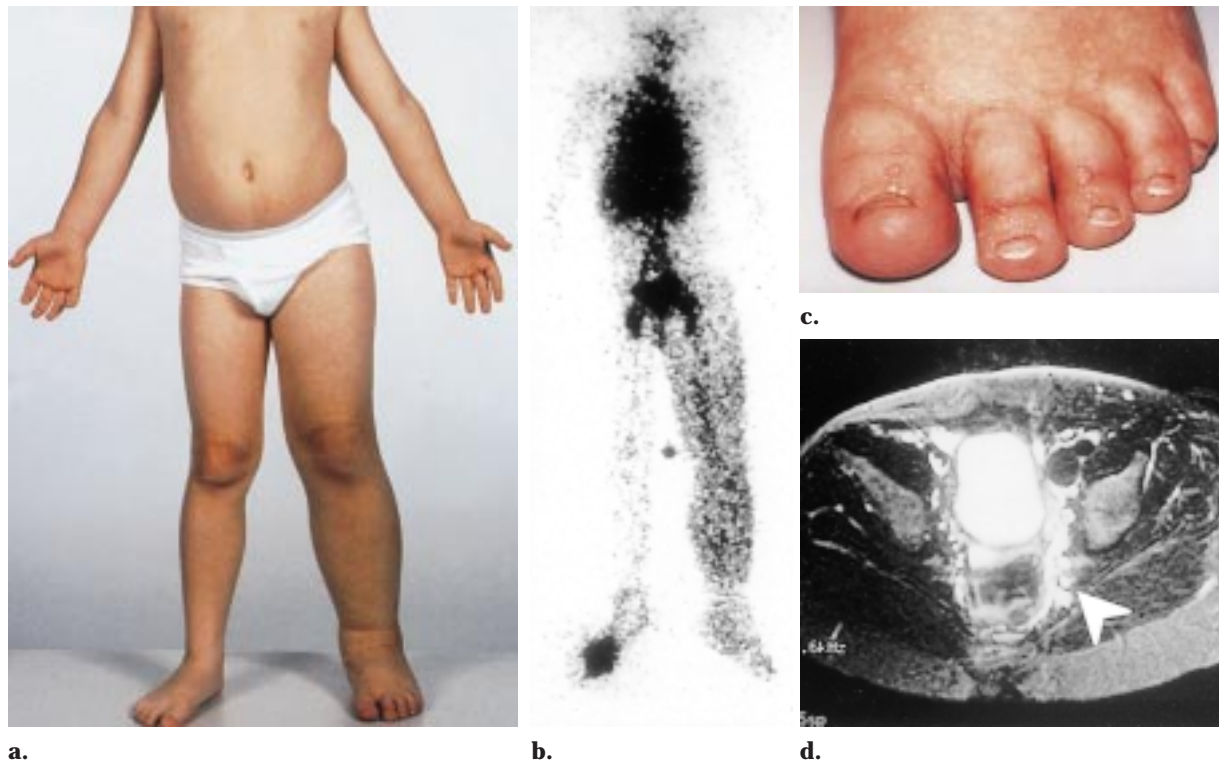

Figure 8. Chylous reflux syndrome in an 8-year-old boy with left leg lymphedema. **(a)** Clinical photograph demonstrates marked enlargement of the left leg. **(b)** Lymphangioscintigram obtained after injection of Tc-99m albumin into the right foot shows rapid transport to the right groin and retroperitoneum with prominent regurgitation throughout the left leg. Lymphangioscintigraphy performed after injection of radiotracer into the left foot demonstrated only dermal backflow, a finding that is consistent with lymphatic hypoplasia. **(c)** Close-up clinical photograph of the left foot demonstrates prominent "milky vesicles" and edema, findings that are consistent with a chylous reflux syndrome. **(d)** Transaxial CT scan of the pelvis shows prominent perirectal lymphatic vessels (arrowhead), a finding that is consistent with a primary chylous reflux syndrome (intestinal lymphangiectasia).

In secondary lymphedema and in lymphedema precox and tarda, the TIS is generally abnormally high although variable, which suggests both congenital and acquired causes. Retarded lymph transport or faint or absent nodal visualization typically contribute to the abnormally high TIS.

In some patients with lower-extremity lymphedema, lymphatic dysplasia also involves the viscera, and peripheral edema is compounded by reflux of retroperitoneal and even mesenteric (intestinal) lymph. Because ingested triglycerides are transported as opalescent chylomicra in lymph, some of these reflux disorders are characterized by regurgitation of intestinal (lacteal) lymph into chylous skin vesicles or external leakage of milky lymph. Lymphangioscintigraphy and MR imaging are particularly useful in demonstrating regurgitation of lymph in these reflux syndromes (Figs 8, 9).

In summary, lymphangioscintigrams obtained in patients with primary lymphedema display absent or delayed radiotracer transport after intra-

dermal injection, absence or paucity of lymphatic collectors, dermal diffusion (backflow), and poorly visualized or absent regional lymph nodes, a constellation that is diagnostic in the absence of a history of prior cancer chemotherapy, nodal extirpation or irradiation, or severe trauma.

Secondary Lymphatic Dysplasia

Secondary lymphatic dysplasia has a multitude of causes, but underlying each is obstruction of lymph flow from an acquired cause. In developed countries, the most common antecedent is treatment for cancer. Thus, as part of staging or eradication of localized malignancies, regional lymph nodes (and hence their afferent and efferent lymphatic connections) are excised, irradiated, or obliterated. For example, staging of breast cancer currently includes axillary dissection, whereas treatment of malignant melanoma (especially in cases involving thick lesions or deep dermal invasion) often includes regional nodal dissection. Although the occurrence of subsequent peripheral lymph-

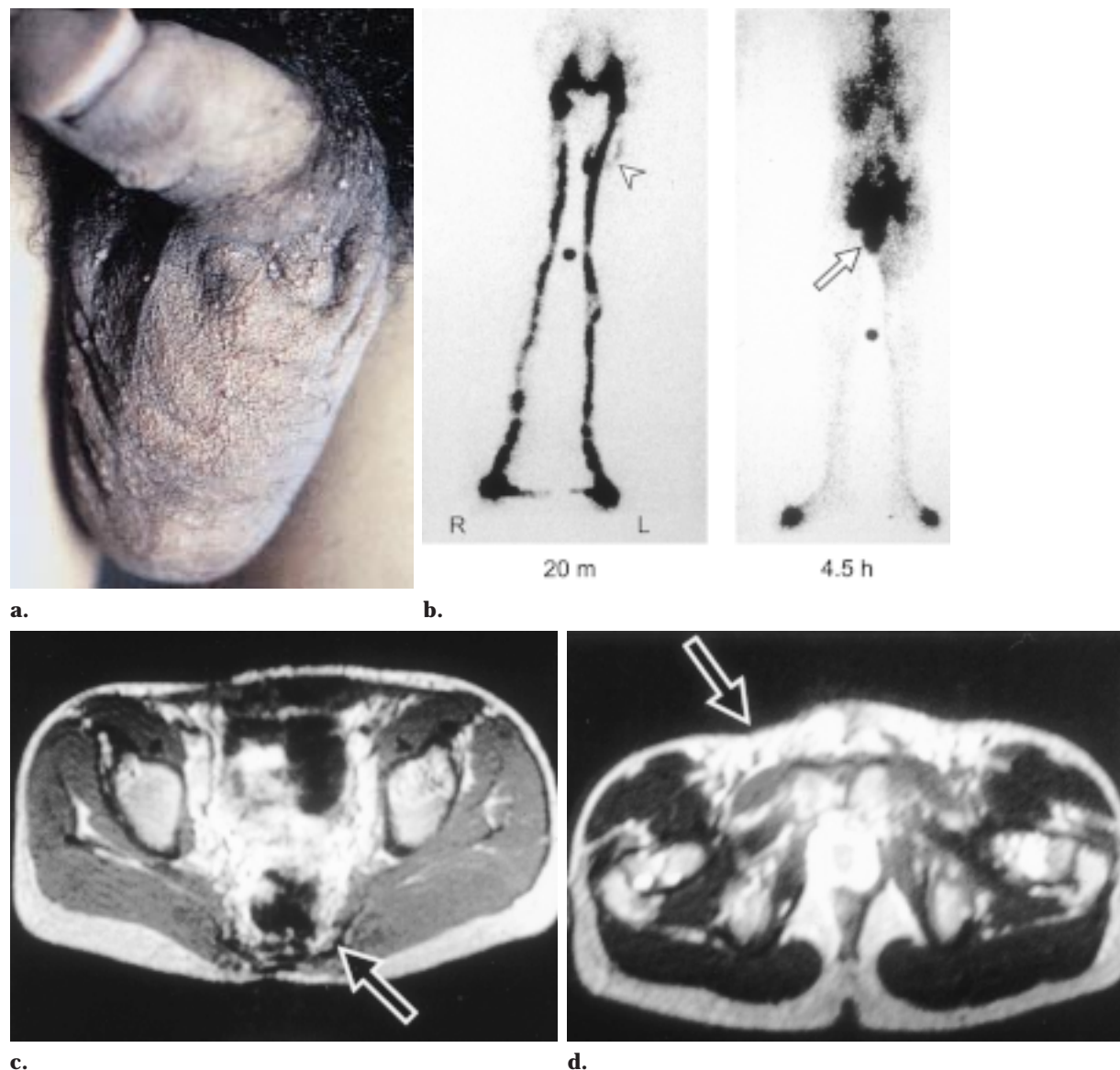


Figure 9. Chylous reflux syndrome in a 12-year-old boy. **(a)** Clinical photograph shows chylous vesicles of the scrotum. **(b)** Lymphangioscintigrams obtained 20 minutes (left) and 4½ hours (right) after injection of radiotracer show intact lymphatic trunks with prompt transport but with slight thigh dermal backflow (arrowhead) and scrotal filling (arrow). **(c, d)** Transaxial T2-weighted MR images show prominent perirectal lymphatic vessels (arrow in **c**) and pubic skin with superficial lymphangiectasia (arrow in **d**).

edema is unpredictable, it is well established that the more extensive the regional node dissection, the wider the irradiation field and the greater the dose, and especially when both treatment modalities are combined, there is a higher prevalence and a greater severity of subsequent lymphedema (10). On the other hand, it is not uncommon for lymphedema to appear months, years, or even decades after the initial insult (nodal dissection or irradiation), so that the true prevalence of this complication is still not fully known. The prolonged delay seems to be related to gradual dete-

rioration in the propulsive intrinsic contractile force of the lymphatic wall (a key pathomechanism of lymph transport) and progressive valve incompetence (11,12). As with heart failure secondary to essential hypertension or aortic stenosis with increased cardiac work against greater resistance to blood flow, the lymphatic system gradually fails after nodal dissection because, over time, lymphatic pumping requires greater work and contractile force to overcome unremitting restriction to the free flow of lymph.

Lymphangioscintigraphic Patterns in Primary versus Secondary Lymphedema

Type of Lymphedema	Lymphatic Collectors	Nodal Visualization	Tracer Dispersion (Dermal Backflow)
Primary			
Hypoplasia	Poorly defined	Delayed	Early, prominent
Aplasia	Not seen	Faint or absent	Little or none
Secondary	Discrete (especially early)	Delayed, faint or absent	Delayed, variable but usually prominent late

Note.—Both early (<20 minutes after radiotracer injection) and late (>3 hours after injection) scintigrams should be obtained.

In contrast to secondary lymphedema in developed countries, acquired lymphedema in undeveloped or third-world countries is often caused by filariasis or other infectious processes. Transmitted in larval form by insect vectors, the adult filarial nematode takes up residence in the peripheral lymphatic vessels and nodes. Seemingly impervious to the host defense mechanisms (lymph nodes, lymphocytes, circulating lymph) or else confusing them by molecular mimicry, the active worms interfere with lymph flow, and in extreme cases the involved limb or genitalia take on an elephantine or pachydermatous appearance. Some patients have predominant or concomitant visceral lymphatic involvement, which may culminate in conditions such as chyluria, hydrocele, chylous reflux (chylometrorrhagia or chylous vesicles), genital edema, or even massive breast engorgement (13). Because many patients in endemic areas often walk barefoot, it is thought that overt or subclinical bacterial infection contributes to the grotesque deformities often associated with these parasitic conditions (14).

Although cancer treatment and infectious processes explain the presence of secondary lymphedema in the majority of affected patients, there is a wide variety of other etiologic factors. For example, lymphatic dysfunction that accompanies long-standing venous disease or occurs after venous stripping and ligation or secondary to extensive lymphatic infiltration directly by invasive cancer may contribute to or produce leg or arm swelling. There are also many patients in whom the cause of edema is unclear. In these individuals, the disease is often termed lymphedema tarda because limb swelling commences later in

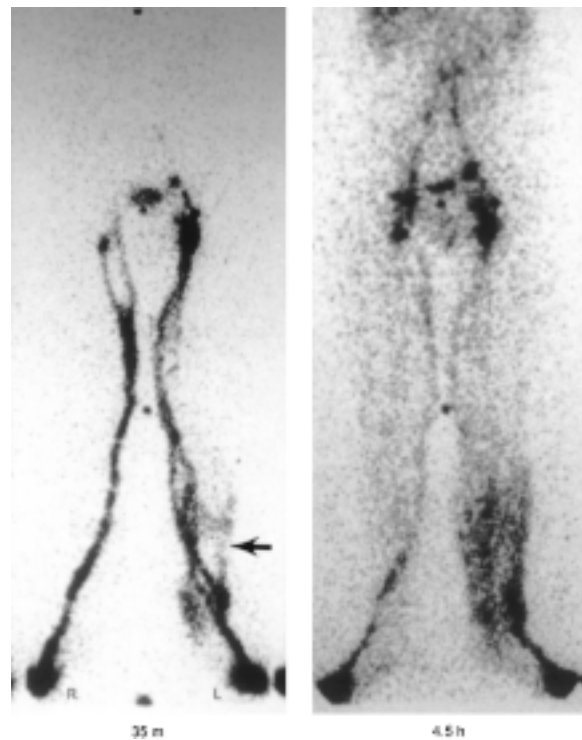


Figure 10. Idiopathic secondary (acquired) lymphedema in a 58-year-old man with sudden onset of unexplained lower left leg edema. Duplex Doppler US showed a patent deep venous system with competent intraluminal valves. Lymphangioscintigrams obtained 35 minutes (left) and 4½ hours (right) after injection of radiotracer show intact deep trunks but with dermal backflow (arrow on earlier image) and accumulation in the lower left leg (later image). These findings are consistent with idiopathic secondary lymphedema.

life (ie, after the age of 30 years). Lymphedema tarda has generally been viewed as congenital in origin with a delayed manifestation, but the late onset and lymphangioscintigraphic findings often

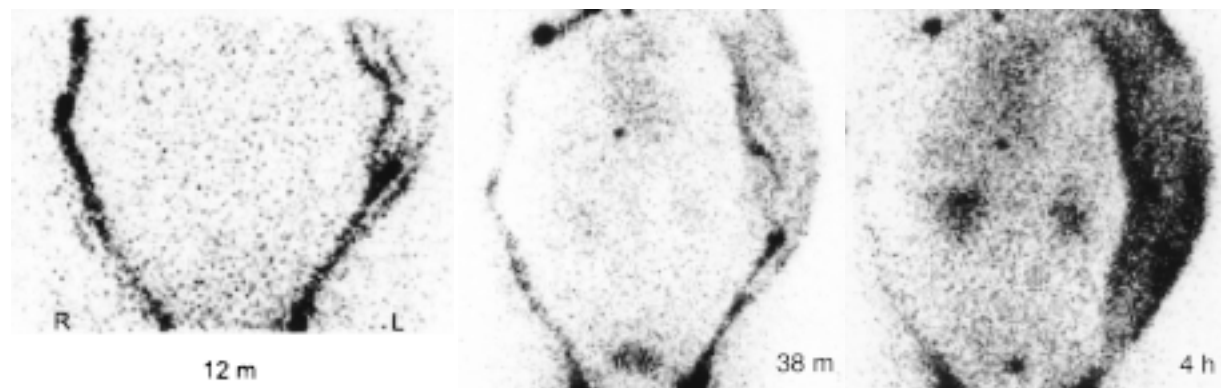


Figure 11. Secondary (acquired) lymphedema of the left arm in a 64-year-old woman. The patient had undergone modified radical mastectomy and regional irradiation for breast cancer 3 years earlier. Sequential lymphangioscintigrams obtained 12 minutes (left), 38 minutes (middle), and 4 hours (right) after injection of radiotracer show initially intact deep trunks with progressive dermal backflow in the left arm. These findings are compatible with acquired or secondary lymphedema (cf Figs 3–5).

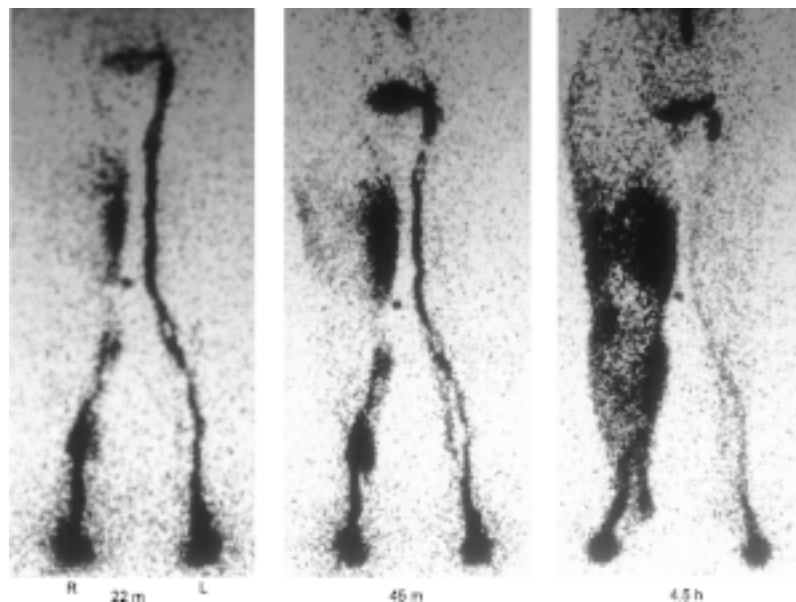


Figure 12. Secondary (acquired) lymphedema of the right leg in a 37-year-old woman. The patient had undergone radical hysterectomy and retroperitoneal irradiation for uterine carcinoma 6½ years earlier. Lymphangioscintigrams obtained 22 minutes (left), 45 minutes (middle), and 4½ hours (right) after injection of radiotracer demonstrate initially intact lymphatic trunks but with progressive dermal backflow in the right thigh and hip. These findings are consistent with secondary lymphedema (cf Figs 3–5).

suggest a secondary or acquired cause (Fig 10). Like lymphedema precox, which is usually attributable to lymphatic hypoplasia, lymphedema tarda may also be associated with nodal dysplasia and lymphatic obstruction, which suggests an acquired cause. To a large extent, new insights into these poorly understood disease entities and other edema syndromes derive from the ability to readily image the lymphatic system. Of the various imaging modalities, whole-body lymphangioscintigraphy continues to show the greatest promise.

Secondary Lymphedema

Although in many respects lymphangioscintigraphic findings in secondary lymphedema resemble those in primary lymphedema, there are nonetheless notable differences (Table). As one would expect with obstruction, lymphatic trunks are often prominent (Figs 11, 12), in contrast to their attenuation or absence in congenital or hypoplastic syndromes. Although collectors-trunks

are eventually obliterated (“die-back”) owing to lymph stagnation, intraluminal coagulum-gel deposition, and reactive inflammation during continued or long-standing lymphatic obstruction, some residual lymphatic truncal activity is usually seen, particularly in the first few minutes after intradermal radiotracer injection. Regardless of the cause, however, secondary (like primary) lymphedema is typically accompanied by dermal diffusion (backflow). The latter is intense and is typically seen early after injection in primary lymphatic dysplasia but is more variable in secondary lymphedema depending on severity and chronicity. Thus, it is essential not only that early scintigrams (<30 minutes after radiotracer injection) be obtained to visualize truncal activity (Figs 11, 12), but also that late scans (3–5 hours after injection) be obtained to detect delayed dermal backflow (Fig 13) before a lymphangioscintigraphy study can be considered complete. We have also found that the whole-body “sweep” technique provides not only an accurate topographic image but also a global overview of the lymphatic system so that subtle focal dermal backflow and retrograde lymph flow are not missed (Fig 14). Other abnormalities such as delayed radiotracer transport and faintly visualized regional lymph nodes are also common after secondary lymphatic damage. However, as indicators of lymphatic dysfunction as the underlying cause of limb swelling (ie, lymphedema), they are characteristically also accompanied by dermal backflow of radiotracer. Occasionally, as in filariasis (14) or acquired immunodeficiency syndrome (AIDS)-related Kaposi sarcoma (15), mild lymphedema may be accompanied only by ectatic lymphatic vessels and sluggish lymph flow. Although lymphangioscintigraphy is not comparable to direct lymphography in depicting intranodal architecture, it is nonetheless exquisitely sensitive to even subtle lymphatic damage and dysfunction. For example, after topical use of the vesicant cantharone for eradication of plantar warts, acute lymphangitis may super-

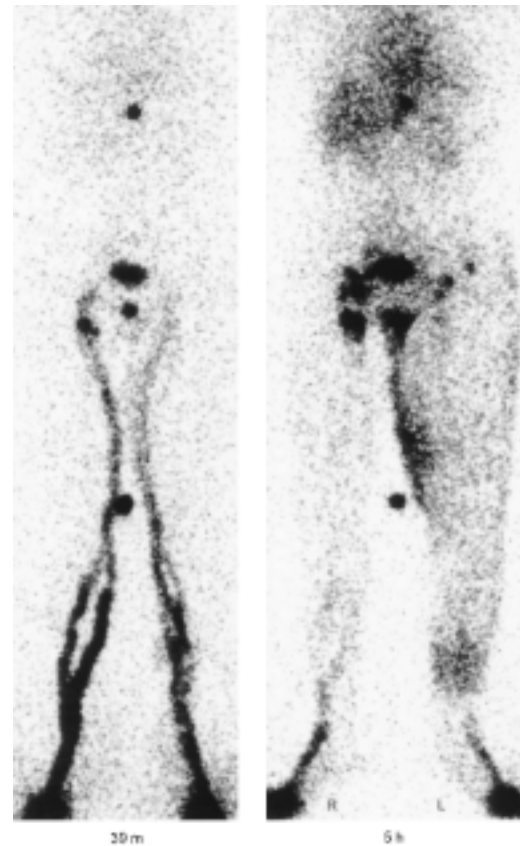
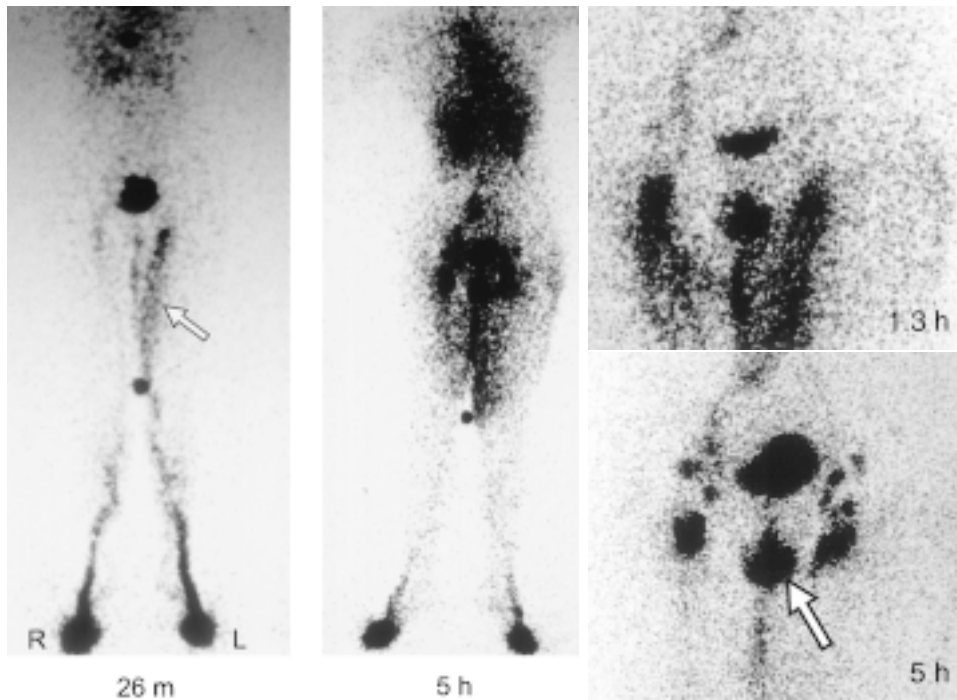
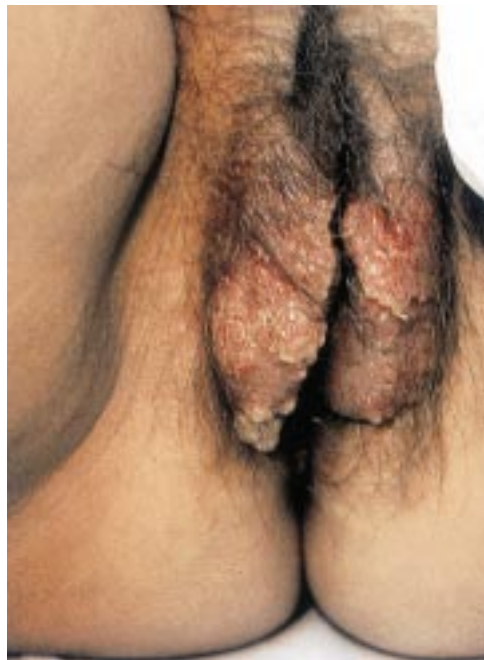

Figure 13. Secondary lymphedema of the left leg in a 72-year-old man. The patient had undergone radical prostatectomy for prostate adenocarcinoma 4 years earlier. Lymphangioscintigrams obtained 39 minutes (left) and 5 hours (right) after injection of radiotracer demonstrate very faint dermal backflow in the left calf and thigh on the earlier image and marked accumulation in superficial skin lymphatic vessels on the later image. These findings illustrate the importance of early scintigrams in visualizing the deep lymphatic collectors and of late scintigrams in evaluating dermal backflow in secondary lymphedema.

vene and, on rare occasions, may culminate in chronic focal lymphedema (16). Similarly, minor soft-tissue trauma, bone fractures, or injection or stripping of venous varicosities may induce both subtle and prominent lymphatic dysfunction (Fig 15). Again, however, clinical findings should be



b.



a.

c.

Figure 14. Vulval edema in a 45-year-old woman who had undergone radical hysterectomy for uterine carcinoma. **(a)** Clinical photograph demonstrates marked vulval edema. **(b)** Lymphangioscintigrams obtained 26 minutes (left) and 5 hours (right) after injection of radiotracer show intact deep lymphatic trunks with dermal backflow in the left upper thigh (arrow) and accumulation in the vulva. **(c)** Close-up lymphangioscintigrams obtained 1.3 (top) and 5 (bottom) hours after injection of radiotracer show prominent dermal backflow in the left upper thigh and accumulation in the vulva (arrow).

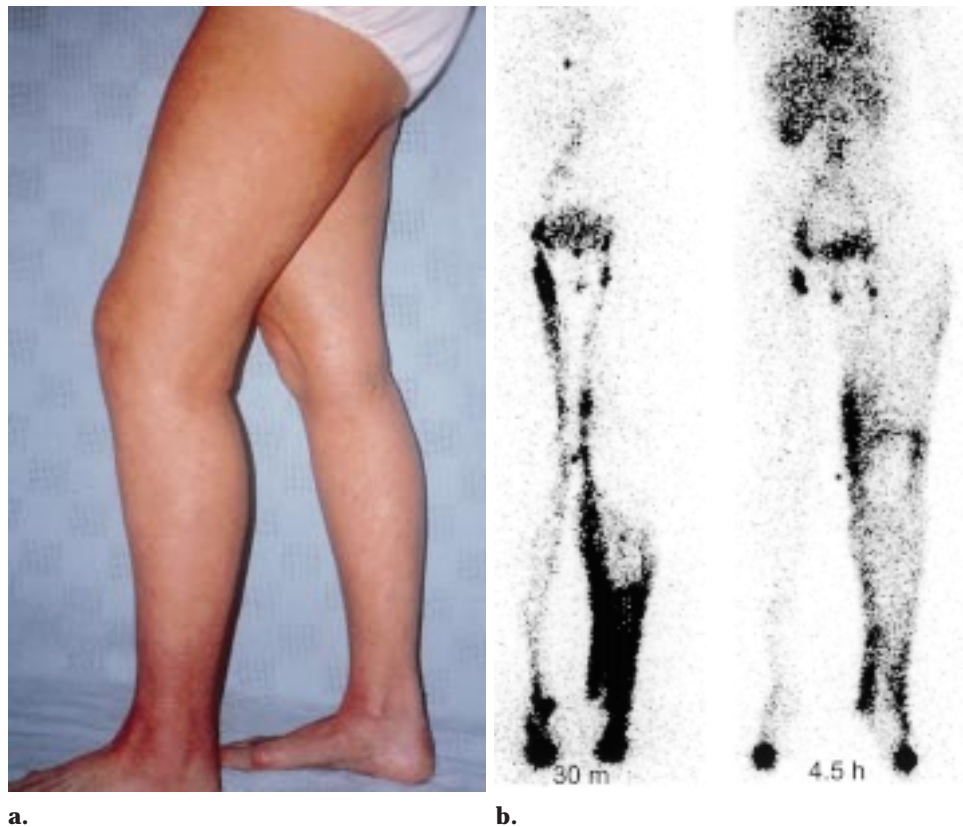


Figure 15. Left lower leg edema in a 51-year-old woman who had undergone liposuction and stripping and ligation of varicose veins. **(a)** Clinical photograph demonstrates enlargement of the left leg. **(b)** Lymphangioscintigrams obtained 30 minutes (left) and 4½ hours (right) after injection of radiotracer show lymphatic collectors on the patient's left side but with dermal backflow and poor clearance of the radiotracer on the later image. Radiotracer transport and clearance in the right leg is unremarkable.

correlated with scintigraphic findings. Often, the lymphatic changes are minor or focal and radiotracer clearance from the limb is prompt, so that the clinical condition of whole-limb swelling cannot properly be attributed solely to lymphatic dysfunction. On the other hand, even where lymphatic blockage is documented, the underlying

disorder may emanate from an extralymphatic cause (Fig 16).

Similar lymphatic patterns of secondary lymphedema are seen in filariasis. In studies conducted primarily in southern India, where *Wuchereria bancrofti* and *Brugia malayi* are endemic, a wide range of pathologic conditions were depicted at scintigraphy depending on the severity of the peripheral edema (14). Thus, lymphangiectasia,

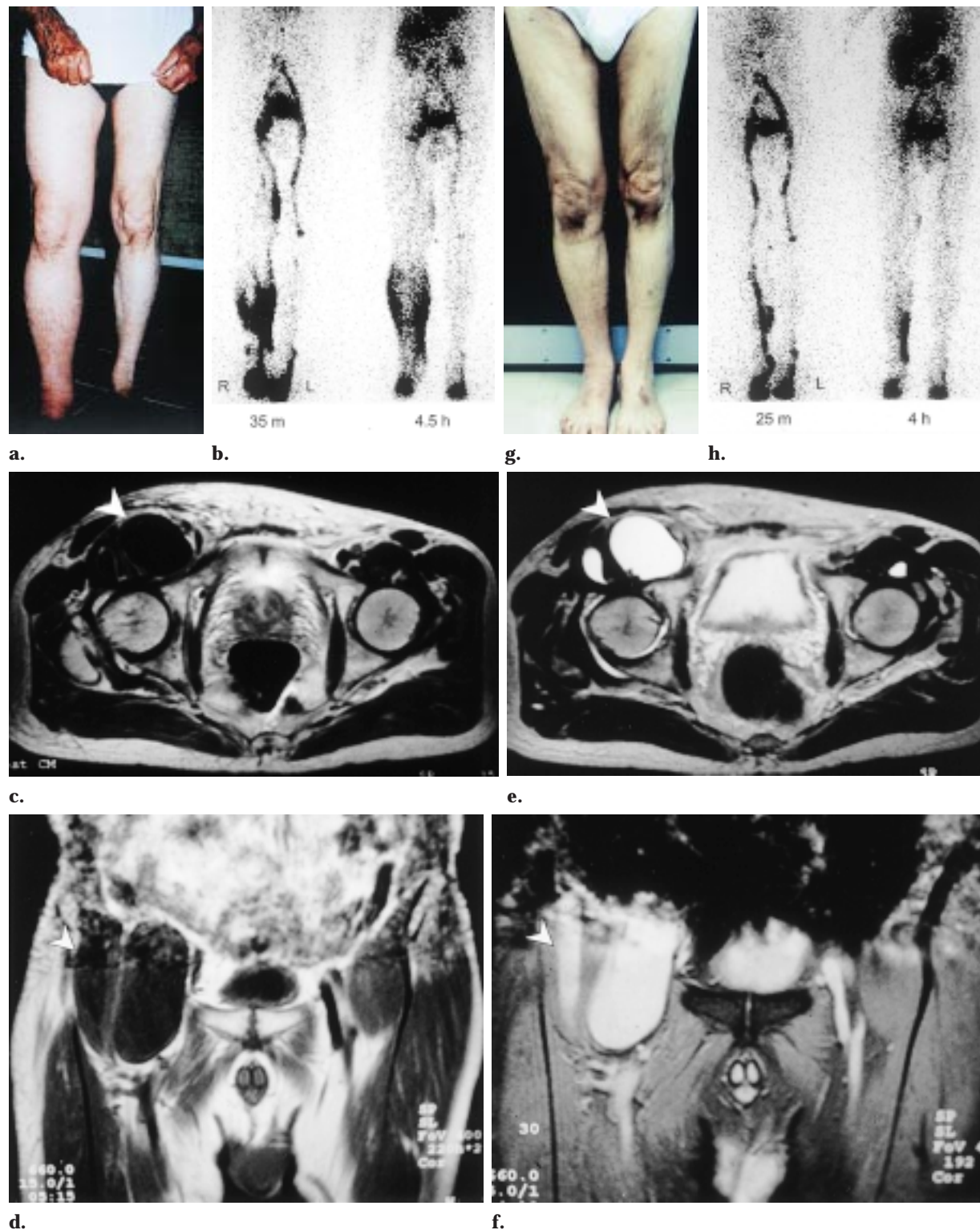
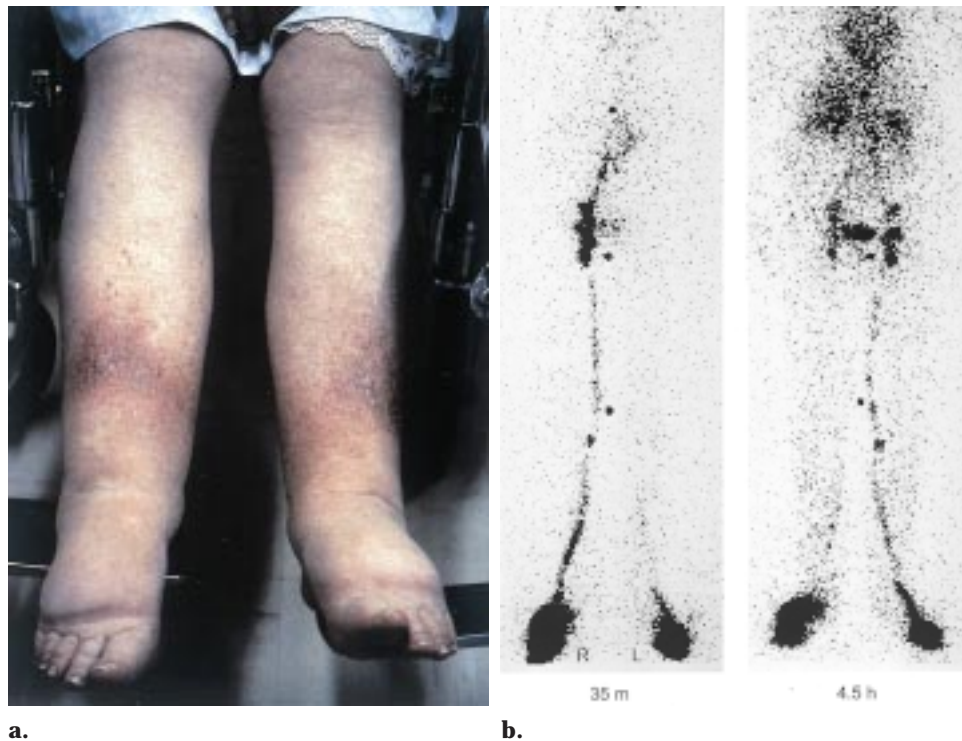
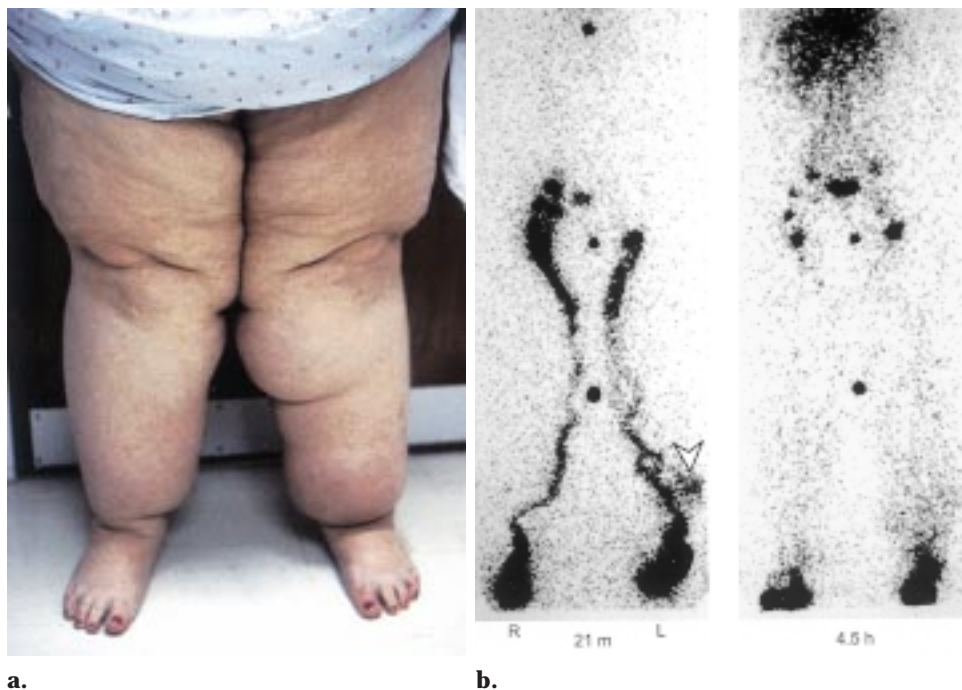


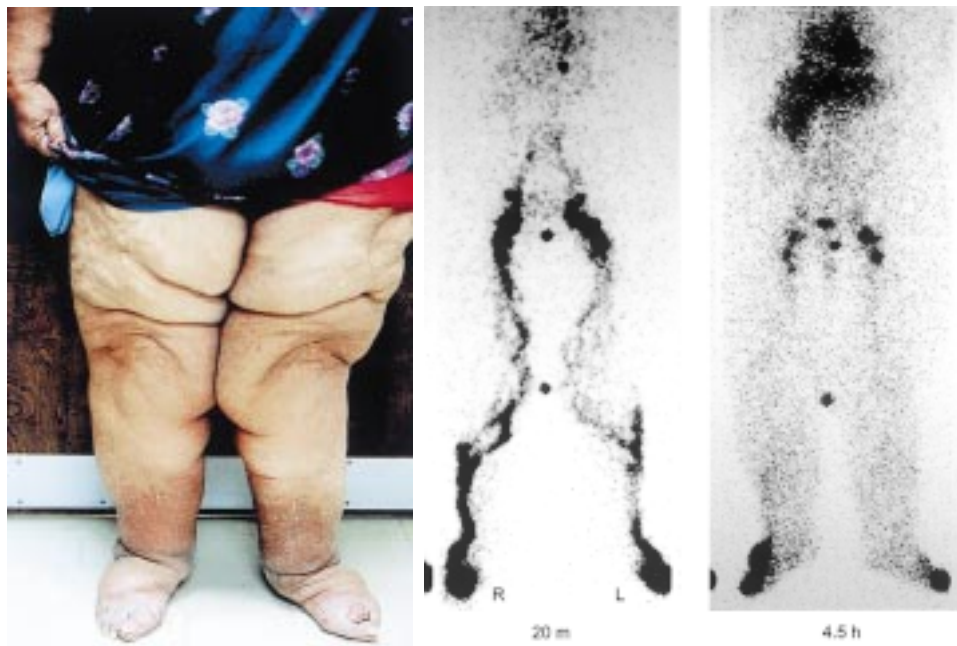
Figure 16. Right leg lymphedema and groin mass in a 72-year-old man. **(a)** Clinical photograph shows marked enlargement of the right leg. **(b)** Presurgical lymphangioscintigrams obtained 35 minutes (left) and 4½ hours (right) after injection of radiotracer demonstrate prominent dermal backflow in the right leg with intact trunks superiorly, findings that are suggestive of secondary lymphedema. **(c, d)** Transaxial **(c)** and coronal **(d)** T1-weighted MR images display a large cystic mass (arrowhead) communicating with the right hip joint. **(e, f)** Transaxial **(e)** and coronal **(f)** T2-weighted MR images demonstrate findings similar to those seen at T1-weighted imaging (arrowhead) (cf **c, d**). **(g)** Clinical photograph taken 6 weeks after excision of a large synovial cyst demonstrates resolution of overt edema. **(h)** Repeat lymphangioscintigrams obtained 25 minutes (left) and 4 hours (right) after injection of radiotracer show only minimal residual dermal backflow in the right calf. The patient remains free of peripheral edema 2½ years later.



a. **b.**
Figure 17. Marked peripheral edema in a 79-year-old woman who was wheelchair-bound due to bilateral hip arthritis. The deep venous system was unremarkable at duplex Doppler US. **(a)** Clinical photograph shows bilateral lower leg edema. **(b)** Lymphangioscintigrams obtained 35 minutes (left) and 4½ hours (right) after injection of radiotracer show intact lymphatic trunks without dermal backflow but with sluggish lymph transport, findings that are consistent with functional or “disuse” lymphedema.



a. **b.**
Figure 18. Obesity with distal lymphatic dysfunction in a 34-year-old woman. **(a)** Clinical photograph demonstrates marked enlargement of the legs. **(b)** Lymphangioscintigrams obtained 21 minutes (left) and 4½ hours (right) after injection of radiotracer show bilateral intact but tortuous lymphatic trunks corresponding to rolls of fat. Slight dermal backflow is seen in the lower left leg (arrowhead). These findings demonstrate that morbid obesity is the primary contributor to marked enlargement of the legs in this patient, with lymphedema being a minor component.



a. **b.**
Figure 19. Obesity with no lymphatic dysfunction in a 68-year-old woman. **(a)** Clinical photograph demonstrates marked enlargement of the legs. **(b)** Lymphangioscintigrams obtained 20 minutes (left) and 4½ hours (right) after injection of radiotracer show intact lymphatic trunks and good clearance. Prior duplex Doppler US showed the iliofemoral-popliteal veins to be patent with minimal valvular incompetence. These findings indicate that morbid obesity is the primary abnormality in this case.

dermal backflow, poor nodal visualization, hydrocele “filling,” perirenal extravasation (in chyluria), and even chylous reflux or total absence of transport are characteristic.

Confinement to a wheelchair or other sedentary conditions of disuse may be associated with peripheral swelling. Lymphangioscintigraphy demonstrates sluggish lymph flow (Fig 17) but eventual clearance of the radiotracer, albeit slowly and without dermal diffusion. Therefore, it is unlikely that a structural abnormality of the lymphatic system is a primary contributor to the genesis of edema.

Morbid obesity is another condition worthy of special consideration. Affected patients often present with large, heavy legs, corpulent buttocks, and bulky upper arms (16). On the other hand, it cannot be determined from mere inspection alone

whether lymphatic dysfunction is causative or contributory to limb enlargement. Typically, in this form of obesity, the feet are small and lack a dorsal hump, reminiscent of genetic forms of obesity such as Prader-Willi syndrome. Unfortunately, these findings are not pathognomonic; an obese patient may have dorsal humps, whereas a patient with lymphedema may not have notable changes in the feet. Whole-body lymphangioscintigraphy is a rapid, definitive means of depicting the peripheral lymphatic circulation. In some instances, massive obesity may be accompanied by a component of distal lymphatic dysfunction (Fig 18). In other instances with a similar clinical appearance, no restriction to lymph flow is documented (Fig 19).

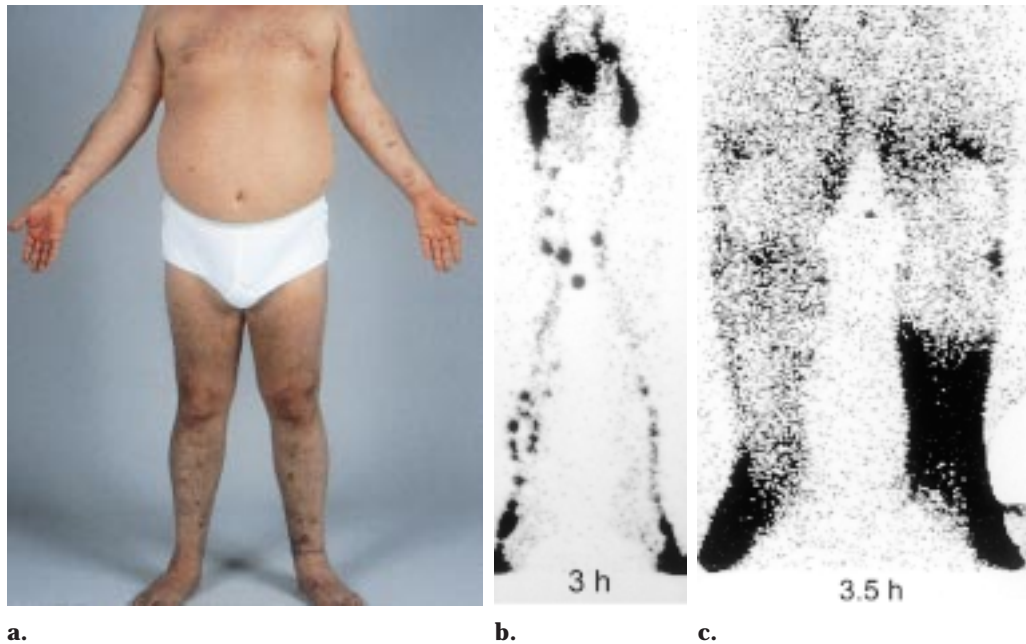


Figure 20. Progressive lymphedema in a 47-year-old man with Kaposi sarcoma and AIDS. **(a)** Clinical photograph demonstrates Kaposi lesions on the extremities. **(b)** Lymphangioscintigram obtained at the time the clinical photograph was taken (3 hours after injection of radiotracer) shows minimal edema with uninterrupted lymph flow and intact lymphatic vessels but with cutaneous "hot spots" corresponding to Kaposi lesions (cf **a**). **(c)** Lymphangioscintigram obtained 5 years later (3½ hours after injection of radiotracer) when the patient had considerably more leg edema with Kaposi skin lesions that had progressed to confluence shows marked dermal backflow.

Kaposi sarcoma is a proliferative "tumor" of the microvasculature that is often associated with AIDS. The cell of origin is likely lymphatic endothelium (18,19), and lymphangioscintigraphy in these patients not only shows the Kaposi sarcoma skin lesions but, if continued spreading and dermal lymphatic obliteration are present, documents progressive lymphedema (Fig 20) (15).

Other Modalities in the Evaluation of Lymph Flow Disorders

MR Imaging

Although it is costly and therefore currently of only limited usefulness in the evaluation of peripheral lymphedema, MR imaging has yielded both practical and pathophysiologic information about this condition. First, like CT, MR imaging can demonstrate visceral conditions such as intra-abdominal lymphoma or some other malignancy

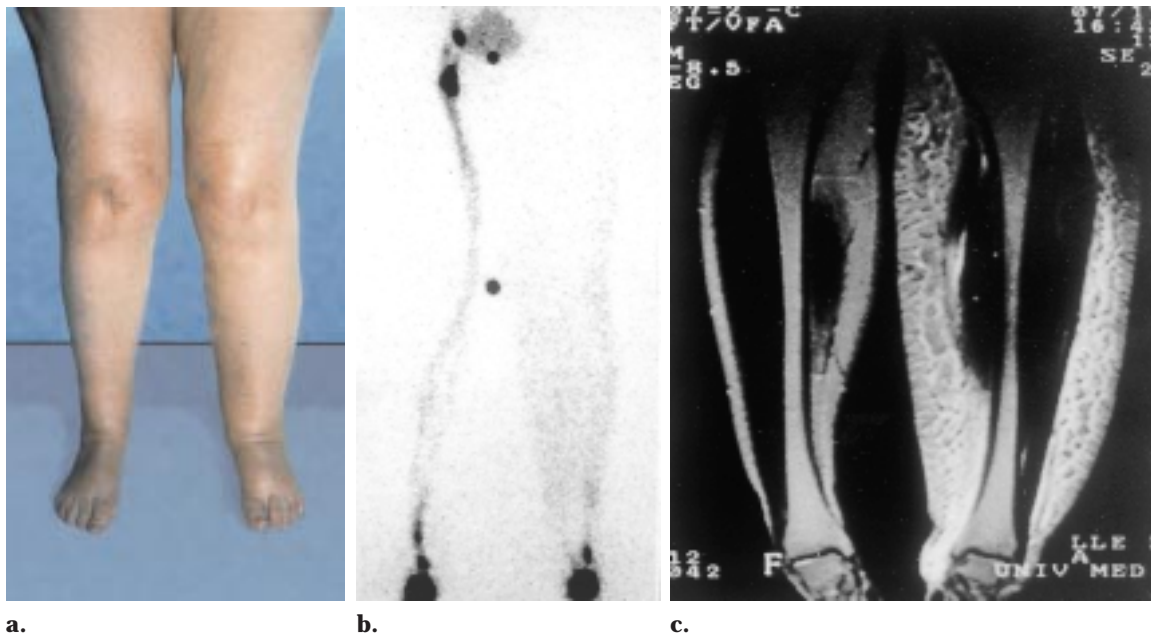


Figure 21. Primary lymphedema of the left leg in a 42-year-old woman, who had had the disease since childhood. **(a)** Clinical photograph shows enlargement of the left leg. **(b)** Lymphangioscintigram helps confirm marked lymphatic hypoplasia of the left leg. **(c)** Coronal MR image demonstrates marked edema of the subcutaneous tissue in the left leg with no edema in the subfascial (skeletal muscle) compartment.

in an adult patient who presents with unilateral limb lymphedema. Second, in large numbers of patients with lymphedema, assessment of the subfascial (ie, muscular) compartment of the swollen limb demonstrates absence of skeletal muscle edema, thereby helping confirm that lymphedema is primarily a disorder of the skin and subcutaneous tissue (Fig 21) (20). Indeed, this finding explains how even a patient with bulky elephantiasis is able to ambulate with movement restricted only by the cumbersome nature and heaviness of the afflicted extremity. Most likely, the tight fascial binding surrounding the skeletal muscles serves as an effective coun-

teracting force to offset most capillary filtration from microvascular hydrostatic pressure. This natural biologic barrier has its treatment counterpart in the use of combined physiotherapy and external compression (pneumatic devices, elastic garments) to minimize swelling in peripheral lymphedema (21). In fact, when severe muscle edema occurs (eg, after reperfusion injury or extensive trauma), because of the relatively limited capacity of the subfascial lymphatic network, prompt fasciotomy is necessary to allow edema fluid to escape, thereby decompressing the closed

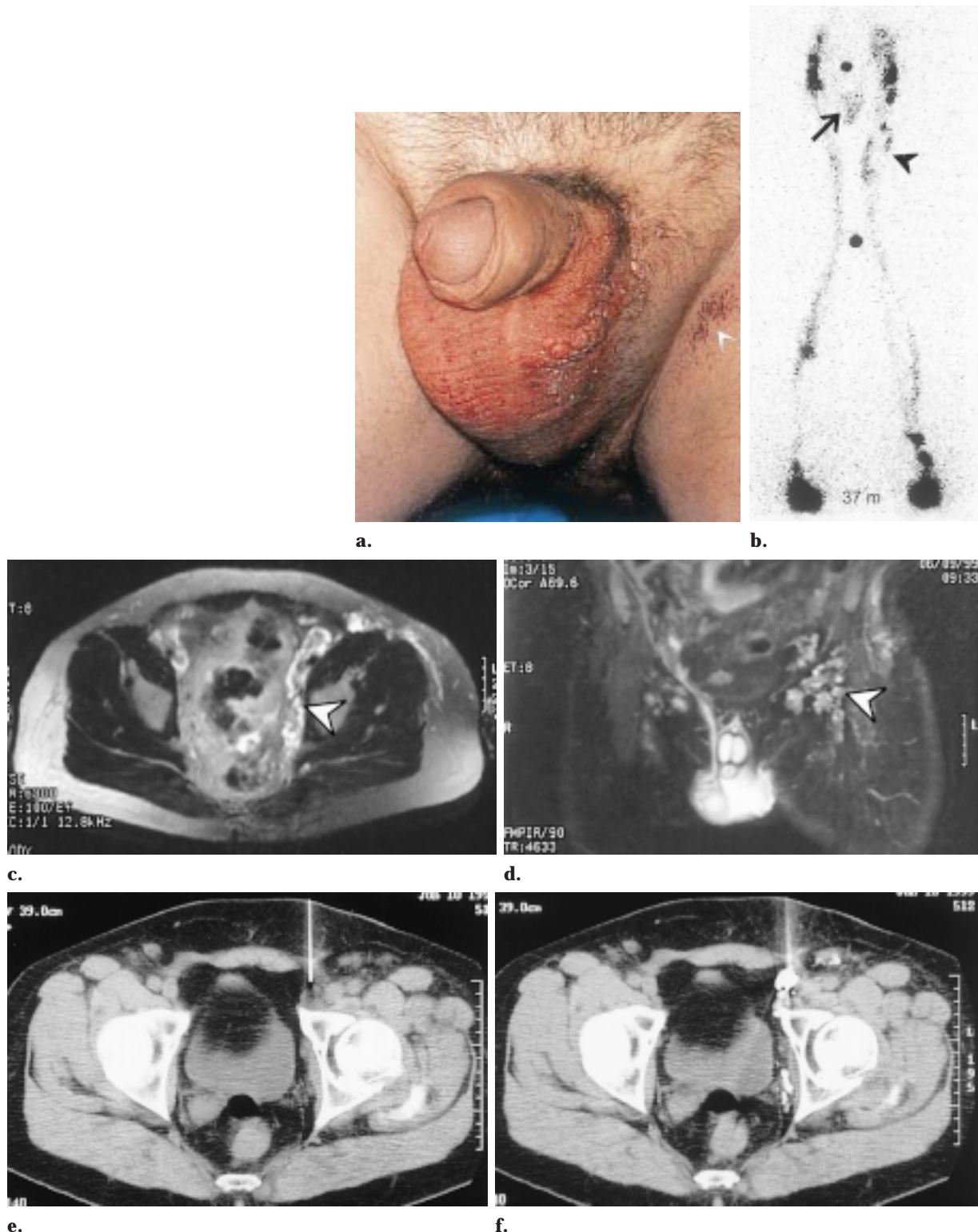


Figure 22. Chylous reflux syndrome in a 42-year-old man. **(a)** Clinical photograph shows chylous vesicles of the scrotum with intermittent leakage of milky lymph. The darkened area on the inner aspect of the upper left thigh (arrowhead) represents an abnormal collection of small, intradermal lymphatic vessels (lymphangioma circumscripta). **(b)** Lymphangioscintigram obtained 37 minutes after injection of radiotracer demonstrates intact collectors but with dermal backflow in the upper left thigh (arrowhead) and fistulization to the scrotum (arrow). **(c, d)** T2-weighted MR images demonstrate prominent perirectal lymphatic vessels (arrowhead in **c**) and a lymphangiomatous collection of lymphatic vessels in the thigh corresponding to lymphangioma circumscripta (arrowhead in **d**) (cf **a**). **(e, f)** CT scans of the pelvis demonstrate the technique used to percutaneously obliterate these ectatic lymphatic vessels, thereby minimizing or preventing chylorrhea. After needle localization (**e**), a small amount of contrast material is injected to confirm lymphatic puncture (**f**) before injection of a sclerosing solution (doxycycline). Several injections are often required to achieve cessation of chylous leakage.

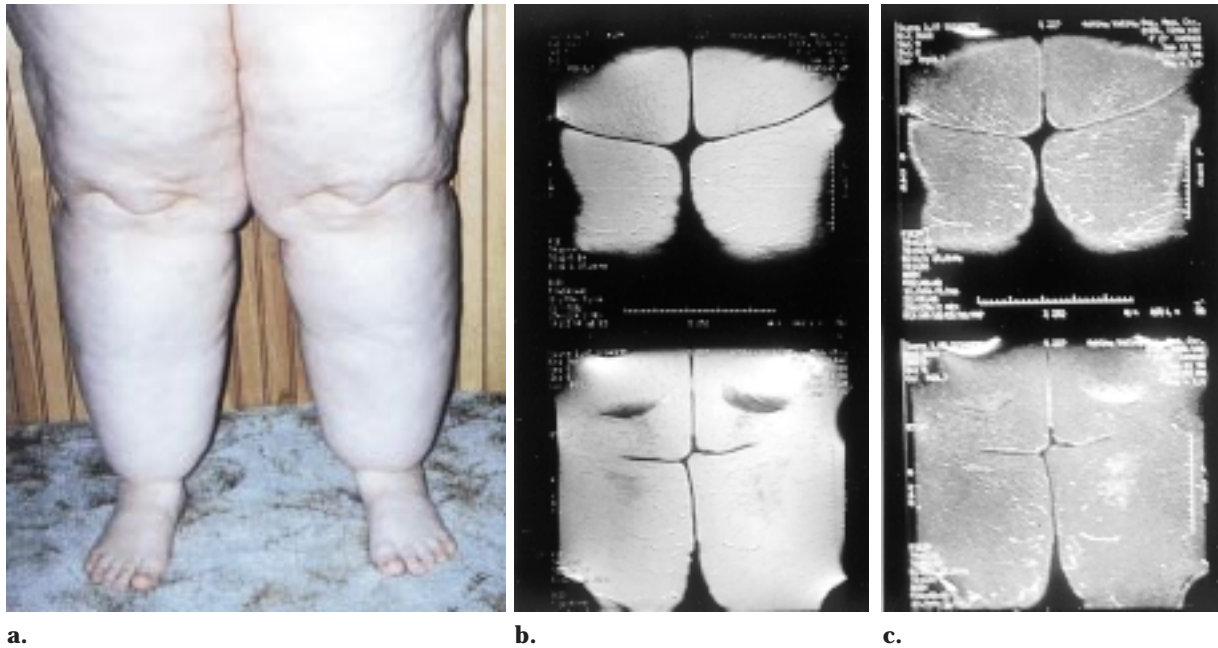


Figure 23. Leg enlargement due to obesity in a 28-year-old woman. The swelling was initially attributed to primary lymphedema. **(a)** Clinical photograph shows marked enlargement of the legs. **(b, c)** Coronal MR images obtained before **(b)** and after **(c)** fat subtraction help confirm that obesity is the primary cause of bilateral leg enlargement in this patient.

compartments and preventing permanent neurologic or ischemic damage (22). Third, MR imaging, sometimes in conjunction with CT, permits visualization of deep-lying, ordinarily inaccessible lymphatic vessels as in the retroperitoneum in chylous reflux syndromes (20,23). Combined transaxial and coronal imaging allows visualization of these lymphatic vessels and provides visual guidance for the injection of sclerosing agents for the obliteration of external lymph leakage (eg, skin, vagina) or bulky lymphangiomas (Fig 22) (23). Fourth, in conjunction with fat subtraction, MR imaging may help clarify that limb enlargement represents fat deposition rather than fluid accumulation (edema) (Fig 23). Fifth, although not as yet of practical value, imaging with superparamagnetic agents such as iron oxide shows promise in highlighting the lymphatic system and especially its nodal architecture by reducing signal intensity (24,25). Similar applications have been proposed for brominated fluorohydrocarbon compounds in conjunction with CT to help visualize regional lymph nodes (26,27).

Ultrasonography

Although the use of US in most patients with peripheral lymphedema is limited to corroboration of excess dermal subcutaneous fluid accumulation, recent findings substantiate the unique role of this modality in the evaluation of filariasis in endemic areas. With use of a standard transducer, Amaral et al (28) were able to detect indwelling motile adult nematodes in the groins of patients in Recife, Brazil, an endemic area for *W bancrofti*. With real-time duplex Doppler US, these investigators corroborated the almost nonstop twisting motion of these adult worms in dilated lymphatic vessels, a phenomenon that was first documented with direct videomicroscopy in ferrets with *B malayi* (29). This work has recently been corroborated in Madras, India, where US is being used to screen for *W bancrofti* infection and to follow up the efficacy of macrofilaricidal agents such as diethylcarbamate (30).

Fluorescein Microlymphangiography

Intradermal injection of fluorescein isothiocyanate dextran allows visualization of the superficial peripheral microvasculature, including the contractility, permeability, and diffusion characteristics of local blood and lymph capillaries (31,32). Diameters of lymph capillaries can be determined from sequential video-recorded images of the injected field. Findings thus far indicate that patients who have had lymphedema since childhood have aplasia of lymphatic microvessels, whereas those in whom lymphedema first appears during puberty (lymphedema precox) have intact lymphatic capillaries (initial lymphatic vessels) in conjunction with hypoplastic lymph trunks more proximally (32).

Discussion

A major stumbling block in understanding, evaluating, and treating peripheral lymphedema has been the difficulty of visualizing lymphatic vessels in living patients. Although conventional oil-contrast lymphography has been the mainstay for depicting lymphatic vessels for more than 40 years, its notable shortcomings and the emergence of CT and MR imaging have severely curtailed its use. However, improvements and refinements in isotope lymphography now make it possible to obtain vivid continuous images of peripheral lymphatic vessels and provide insight into lymph flow dynamics. Moreover, the procedure is essentially noninvasive, easily repeatable, and harmless to the lymphatic vascular endothelium. Besides having the obvious advantage of providing positive evidence of lymph disorders, lymphangioscintigraphy also helps establish that lymphatic truncal anatomy and radiotracer transport are largely intact in patients who appear to have lymphedema but do not (eg, patients in whom enlargement is due to obesity ["lipedema"]).

Although it is costly, MR imaging also shows promise for evaluation of the lymphatic system. T2-weighted imaging, particularly with fat subtraction, depicts pathologic dermal lymphatic vessels without added contrast material as well as more proximal lymph nodes and obstructing masses. With this modality, the subfascial com-

partment in peripheral lymphedema (both congenital and acquired) has been shown to be intact, and lymphedema is confirmed to be primarily a disorder of the skin and subcutaneous tissue (epifascial compartment). Moreover, MR imaging readily permits visualization of retroperitoneal ectatic lymphatic trunks (eg, in chylous reflux syndromes) and allows access for lymphatic truncal obliteration in the management of lymphangiectasia or lymphangioma syndromes characterized by lymph fistulization, often in connection with intestinal (lacteal) lymph retrograde flow (chylous reflux).

Although it is of limited value in lymphedema patients, US has proved useful in evaluating filariasis in endemic areas and shows potential in screening asymptomatic individuals for filaria and monitoring the viability of the adult worms during treatment. Adult nematodes can readily be seen thrashing and undulating vigorously within peripheral lymphatic vessels, which provides new insights into the local prevalence of filariasis (even in the absence of peripheral edema or microfilaremia) and the pathomechanism of filarial lymphedema (physical destruction of intraluminal valves and impaired lymphatic contractility from live worms and lymphatic thrombosis after host immune response to dying or dead worms).

Conclusions

Peripheral lymphatic vessels can now be visualized as easily as arteries and veins have been for several decades. Because lymphangioscintigraphy can readily be performed both before and after treatment, it should become a requisite component of initial and, in some instances, follow-up evaluation of patients with lymphedema, thereby supplementing patient history and physical examination findings. Lymphangioscintigraphy can also be used to evaluate the efficacy of drugs, surgery, and physical methods designed to facilitate lymph flow or reduce lymph formation. Indeed, all patients in whom a provisional diagnosis of peripheral lymphatic dysfunction or idiopathic edema has been made should undergo diagnostic lymphangioscintigraphy and, in some cases, MR imaging to verify the accuracy of the diagnosis, pinpoint the specific abnormality, and provide a blueprint for subsequent therapy.

References

1. Kinmonth JB, Taylor GW, Tracy GB, Marsh JD. Primary lymphedema: clinical and lymphangiographic studies of a series of 107 patients in which the lower limbs were affected. *Br J Surg* 1957; 45: 1-10.
2. Koehler PR. Complications of lymphography. *Lymphology* 1968; 1:117-120.
3. Weissleder H, Weissleder R. Lymphedema: evaluation of qualitative and quantitative lymphoscintigraphy in 238 patients. *Radiology* 1988; 167: 729-735.
4. McNeill GC, Witte MH, Witte CL, et al. Whole-body lymphangiography: preferred method for initial assessment of the peripheral lymphatic system. *Radiology* 1989; 172:495-502.
5. Papendieck CM. Atlas color: temas de angiología pediátrica. Buenos Aires, Argentina: Editorial Médica Panamericana, 1992.
6. Young AE, Ackroyd J, Baskerville P. Combined vascular malformations In: Mulliken JB, Young AE, eds. *Vascular birthmarks*. Philadelphia, Pa: Saunders, 1988; 246-274.
7. Földi M. Diseases of lymphatics and lymph circulation. Springfield, Ill: Thomas, 1969; 39.
8. Ketterings C, Zeddeman S. Use of the C-scan in evaluation of peripheral lymphedema. *Lymphology* 1997; 30:49-62.
9. Kleinhans E, Baumeister RH, Hahn D, et al. Evaluation of transport kinetics in lymphoscintigraphy. *Eur J Nucl Med* 1985; 10:349-352.
10. Segerström K, Bjerle P, Graffman S, Nystrom A. Factors that influence the incidence of brachial oedema after treatment of breast cancer. *Scand J Plast Reconstr Surg Hand Surg* 1992; 26:223-227.
11. Olszewski W. On the pathomechanism of development of postsurgical lymphedema. *Lymphology* 1973; 6:35-51.
12. Clodius L, Altorfer J. Experimental chronic lymphostasis of extremities. *Folia Angiol* 1977; 25: 137-154.
13. Jamal S. Dramatic manifestations of filarial infection (*W. bancrofti*). *Lymphology* 1985; 18:145-147.
14. Witte MH, Jamal S, Williams W, et al. Lymphatic abnormalities in human filariasis as depicted by lymphangiography. *Arch Int Med* 1993; 153: 737-744.
15. Witte MH, Fiala M, McNeill GC, et al. Lymphangiography in AIDS-associated Kaposi's sarcoma. *AJR Am J Roentgenol* 1990; 155:311-315.
16. Stazzone AM, Borgs P, Witte CL, Witte MH. Lymphangitis and intractable lymphedema after treatment with topical cantharidin. *Arch Dermatol* 1998; 134:104-106.
17. Witte MH, Witte CL. Massive obesity simulating lymphedema. *N Engl J Med* 1992; 327:1927.
18. Dorfman RF. Kaposi's sarcoma: evidence supporting its origin from the lymphatic system. *Lymphology* 1988; 21:45-52.
19. Beckstead JH, Wood GS, Fletcher V. Evidence for the origin of Kaposi's sarcoma from lymphatic endothelium. *Am J Pathol* 1985; 119:294-300.
20. Case TC, Witte CL, Witte MH, et al. Magnetic resonance imaging in human lymphedema: comparison with lymphangiography. *Magn Reson Imaging* 1992; 10:549-558.
21. Casley-Smith John R, Casley-Smith Judith R. Modern treatment for lymphoedema. Adelaide, Australia: Lymphoedema Association of Australia, 1994.
22. Thal ER, Snyder WH, Perry MO. Vascular injuries of the extremities. In: Rutherford RB, ed. *Vascular surgery*. 4th ed. Vol 1. Philadelphia, Pa: Saunders, 1995; 713-735.
23. Molitch H, Unger E, Witte C, vanSonnenberg E. Percutaneous sclerotherapy of lymphangiomas. *Radiology* 1995; 194:343-347.
24. Tanoura T, Bernas M, Darakazanli A, et al. MR lymphography with iron oxide compound AMI-227. *AJR Am J Roentgenol* 1992; 159:875-881.
25. Weissleder R, Elizondo G, Wittenburg J. Ultra-small superparamagnetic iron oxide: an intravenous contrast agent for assessing lymph nodes with MR imaging. *Radiology* 1990; 175:494-498.
26. Mattrey RT, Long DC. Potential role of PFOB in diagnostic imaging. *Invest Radiol* 1988; 23(suppl): 298-301.
27. Bernas M, Witte C, Pond G, et al. Enhanced lymphatic imaging using Imagent LN in filaria-infected ferrets. *Lymphology* 1994; 27(suppl):265-269.
28. Amaral F, Dreyer G, Figueredo-Silva J, et al. Live adult worms detected by ultrasonography in human Bancroftian filariasis. *Am J Trop Med Hyg* 1994; 50:753-757.
29. Case TC, Witte MH, Way DL, Witte CL, Crandall CA, Crandall RB. Videomicroscopy of intralymphatic-dwelling *Brugia malayi*. *Ann Trop Med Parasitol* 1992; 86:435-438.
30. Suresh S, Kumaraswami V, Suresh I. Ultrasonographic diagnosis of subclinical filariasis. *J Ultrasound Med* 1997; 16:45-49.
31. Bollinger A, Jaeger K, Sgier F, Seglias J. Fluorescence microlymphography. *Circulation* 1981; 64: 1195-1200.
32. Isenning G, Franzeck UK, Bollinger A. Fluoreszenz-mikrolymphographie am medialen malleolus bei gesunden und patienten mit primärem lymphödem. *Schweiz Med Wochenschr* 1982; 112: 225-231.
33. Pfister G, Saesseli B, Hoffmann U, et al. Diameters of lymphatic capillaries in patients with different forms of primary lymphedema. *Lymphology* 1990; 23:140-144.
34. Witte CL, Witte MH. Physiology and imaging of the peripheral lymphatic system. In: Moore WS, ed. *Vascular surgery*. 5th ed. Philadelphia, Pa: Saunders, 1998; 808-828.